

Rapid Femoral Vein Assessment (RaFeVA): A systematic protocol for ultrasound evaluation of the veins of the lower limb, so to optimize the insertion of femorally inserted central catheters

Fabrizio Brescia¹ , Mauro Pittiruti² , Matthew Ostroff³ 
and Daniele G Biasucci⁴

The Journal of Vascular Access
1–10

© The Author(s) 2020

Article reuse guidelines:

sagepub.com/journals-permissions

DOI: 10.1177/1129729820965063

journals.sagepub.com/home/jva



Abstract

In this paper we describe a new protocol—named RaFeVA (Rapid Femoral Vein Assessment)—for the systematic US assessment of the veins in the inguinal area and at mid-thigh, designed to evaluate patency and caliber of the common and superficial femoral veins and choose the best venipuncture site before insertion of a FICC.

Keywords

Techniques and procedures, ultrasound, assessment, central venous access, patient safety

Date received: 17 July 2020; accepted: 12 September 2020

Background

In recent years, many factors have contributed to improving the practice of central venous access: adoption of bio-compatible and high-pressure resistant materials, institution of multi-professional, multi-disciplinary teams focused on vascular access, and so on. Though, probably, the most important novelty of the XXI century in the field of venous access has been the adoption of ultrasound (US) technology for minimizing the costs and the complications associated with placement of central venous devices.

US technology has proven its benefits on many different aspects of central venous device placement and management:¹ pre-procedural US scan for venous assessment so to identify the most appropriate site for venipuncture;² real-time US-guided puncture and cannulation of the vein, so to make the maneuver faster and safer;³ real-time sonographic detection of possible puncture-related complications (tissue hematomas, intramural hematomas of the vein, pneumothorax, etc.);⁴ US-based tip navigation, to verify the proper direction of the guidewire and/or of the catheter as they are threaded into the vasculature;⁵ US-based tip location by trans-thoracic echocardiography, so to verify the central position of the tip;⁶ US detection of

many post-procedural, non-infective complications (fibroblastic sleeve, catheter-related venous thrombosis, tip migration, etc.).

All of these benefits of US for central venous access are widely demonstrated in the literature, with undeniable favorable effects on safety and cost-effectiveness.^{1–10} The use of US guidance is now recommended by most scientific societies and professional organizations as an integral part of any central venous access procedure. Though, many healthcare practitioners are still reluctant to use US,

¹Unit of Anesthesia and Intensive Care Medicine, Vascular Access Team, Centro di Riferimento Oncologico di Aviano, IRCCS, Aviano, Italy

²Department of Surgery, Fondazione Policlinico Universitario “A.Gemelli” IRCCS, Rome, Italy

³APN/Vascular Coordinator Saint Joseph’s University Medical Center, Paterson, NJ, USA

⁴Department of Anesthesia and Intensive Care, Fondazione Policlinico Universitario “A.Gemelli” IRCCS, Rome, Italy

Corresponding author:

Fabrizio Brescia, Unit of Anesthesia and Intensive Care Medicine and Vascular Access Team, Centro di Riferimento Oncologico di Aviano, IRCCS, Via Gallini 2, Aviano 33081, Italy.

Email: fabriziobrescia@gmail.com

mainly because of lack of education and culture, or—to a lesser extent—because unable to access this technology at point-of-care.¹¹ The operator's experience and the number of procedures performed may be an important predictor of adverse event reduction and may result in improved catheter and patient outcomes, but the actual protection of the patient is guaranteed only if the operator adopts the appropriate methods and appropriate materials.¹¹

As for the choice of the venous approach and the technique of venipuncture, the preference or the personal experience of the operator should not be regarded any longer as an appropriate criteria. The venous approach that is more “comfortable” for the operator is not necessarily the venous approach associated with the maximal safety for the patient. A rational choice of the venous approach should be based on objective anatomical criteria, verified in the specific patient who is candidate to the procedure. This rational, objective evaluation of the anatomic characteristics of the vasculature of each patient is possible by adopting systematically a pre-procedural US scan of the anatomic area where the central venous access device will be inserted. The inappropriate, “automatic” choice of a venous access based only on the habits of the operator is potentially associated with repeated punctures, waste of time, poor clinical outcomes and/or puncture-related complications, due to the lack of knowledge of the possible anatomical variations or pathologic abnormalities of the local veins or the lack of identification of the surrounding structures (arteries, nerve bundles, and organs).¹¹

Another issue is the technique of venipuncture. There are different possibilities of visualization of the vein (short axis; long axis; oblique axis) and of visualization of the needle (out of plane; in plane). Therefore, there may be different techniques of US-guided venipuncture, with different advantages and disadvantages, and different problems in terms of feasibility and safety.¹²

As mentioned above, US is of great benefit in all steps of the central venous access procedure and suggested by many guidelines and studies.^{1–27} In particular, a preliminary US assessment allows to evaluate the status of the vein, its depth, the presence of anatomical or pathological alterations and more specifically its size, so to choose an appropriate catheter/vein (ideal 1:3 or less) and reduce the risk of catheter-related thrombosis.^{2,10} After preprocedural assessment, all the other steps of the maneuver will also benefit of US, as proven by many studies:^{1,2,10,27–29} puncture and cannulation of the vein, detection of early puncture-related complications, tip-navigation, tip location, and finally diagnosis and monitoring of many late non-infectious complications.

In this technical note we will focus on the importance of the preliminary US-based venous assessment, a strategy that allows to evaluate the state of the veins, the anatomical alterations or the presence of pathological conditions as well as to identify the relationship of the vein with the

surrounding structures in order to choose the vein suitable for cannulation and to minimize complications related to the cannulation procedure and late complications related to the presence of the catheter.^{1–5,7,10,15–17,26–28}

Central venous access devices in children and adults are currently classified as centrally inserted central catheters (CICC), peripherally inserted central catheters (PICC) and femorally inserted central catheters (FICC). Systemic and standardized approaches for the preliminary ultrasound evaluation before CICC and PICC insertion have already been developed.

The RaCeVA protocol (Rapid Central Vein Assessment—RaCeVA) is a systematic protocol of US evaluation of the veins of the neck and of the supra/intra-clavicular area, before CICC insertion. This protocol is useful for teaching the different US-guided approaches to the central veins, for helping the operator to consider systematically all possible venous options and for guiding the operator in choosing the most appropriate vein to be accessed, on a rational and well-informed basis. In fact, during the RaCeVA, the operator can rule out venous abnormalities such as thrombosis, stenosis, external compression, anatomical variations of size and shape of the veins, and obtain a full anatomic evaluation for optimum site selection and the best insertion approach for each patient.^{11–17}

The RaPeVA protocol (Rapid Peripheral Vein Assessment) has also been developed, in order to collect relevant anatomical information before positioning a PICC; the RaPeVA allows to choose the most appropriate vein in terms of size, position and depth, and to identify clearly the median nerve and the brachial artery, so to minimize failure, accidental arterial puncture or nerve damage, and also to reduce the risk of thrombosis.³⁰

In this paper we describe a new standardized protocol—named RaFeVA (Rapid Femoral Vein Assessment)—for the systematic US assessment of the veins in the inguinal area and at mid-thigh, so to evaluate patency and caliber of the common and superficial femoral veins and choose the best venipuncture site before insertion of a FICC.

The approval of the Ethical Committee is not necessary since this is a technical note.

The RaFeVA protocol

The superficial femoral vein (SFV) is the direct continuation of the popliteal vein; a few centimeters before the inguinal groove, it merges with the deep femoral vein (DFV), becoming the common femoral vein (CFV). The latter heads up to the posterior margin of the inguinal ligament where it continues into the external iliac vein. In its initial tract, the SFV is located posterior and lateral to the superficial femoral artery (SFA), around which it turns, going up in a helix, to pass posteriorly and subsequently medially. At the inguinal level, the CFV is normally located

Table 1. The seven steps of the Rapid Femoral Vein Assessment (RaFeVA).

	Vascular structures to be assessed	Visualization of the vein
Step 1	Common femoral artery	Short axis
Step 2	Common femoral vein	Long axis
	External iliac vein	
Step 3	Common femoral artery	Short axis
	Common femoral vein	
Step 4	Saphenous vein	Short axis
	Superficial femoral artery	
	Deep femoral artery	
Step 5	Common femoral vein	Short axis
	Superficial femoral artery	
	Deep femoral artery	
	Superficial femoral vein	
Step 6	Deep femoral vein	Short axis
	Superficial femoral artery	
	Superficial femoral vein	
Step 7	Superficial femoral artery	Oblique axis
	Superficial femoral vein	

medially to the femoral arteries (deep and superficial), in a slightly deeper plane. The femoral arteries may completely overlap the CFV in a significant number of cases.³¹

The large caliber and easy localization of CFV, even in patients with severe hypovolemia, make this venous access very convenient in emergency situations. Moreover, the CFV, being a tributary of the inferior vena cava, represents a valid option in all patients in whom the superior vena cava is obstructed and it is not possible to place central catheters via brachial, supraclavicular or infraclavicular veins. Though, when non-tunneled FICCs are inserted in the CFV, the exit site of the catheter is in a unfavorable anatomical location, at the groin level, that is, in a flexion area (which increases the risk of catheter related thrombosis) and in a region exposed to high bacterial contamination, especially in bedridden patients (and this increases the risk of catheter-related infections).³²⁻³⁴ For these reasons, FICC are uncommonly used except for some specific indications: emergency short-term infusions or short-term hemodialysis (non-tunneled FICC); medium-long term intravenous infusions in case of obstruction of the superior vena cava (tunneled FICC). In fact, the strategy of moving the exit site far from the puncture site at the groin—which can be accomplished either by direct puncture of the SFV at mid-thigh or by tunneling the catheter upward (to the abdomen) or downward (to the mid-thigh)—is effective in reducing the risk of extraluminal bacterial contamination.^{32,33}

Several studies show that US guidance significantly reduces early mechanical complications, late infectious and thrombotic complications, the number of attempts and the costs not only for PICC and CICC, but also during FICC insertion.^{1,34} In a recent guideline, a panel of experts have suggested that the benefits of US guidance documented in

other studies for CFV might be extended to venous access to SFV.¹ This is very interesting from the clinical point of view, since the exit site of a non-tunneled FICC inserted in the SFV is located at mid-thigh, that is, far from the inguinal fold, in a clean, flat and stable area where dressings can be managed optimally, reducing the risk of infection and thrombosis.

As well as RaCeVA and RaPeVA, RaFeVA is a clinical tool to evaluate different approaches to the veins of the groin and mid-thigh region, to provide operators with a systematic sequence for US evaluation of all the veins in the region with the aim of choosing the most appropriate vein for a tunneled or non-tunneled FICC.

RaFeVA consists of seven steps (Table 1), corresponding to seven different positions of the probe. It should always be performed bilaterally.

The veins can be visualized in “short-axis” (SA), in “long-axis” (LA) and in “oblique-axis” (OA) views, depending on the spatial relationship between the plane of the probe and the axis of the vein. The SA and the LA view (Figure 1) have been well described in the literature; the OA view is less common and can be obtained starting from the position of the probe in short axis and subsequently making a rotation of 45^{12,13} (Figure 2).

Venipuncture techniques are also defined by the relationship between the probe and the needle. Regardless of the vessel views, the needle can be advanced “out-of-plane” (OP), that is, perpendicular to the plane of the probe, or “in-plane” (IP), that is, within the plane of the probe.^{12,15} Thus, each venipuncture technique can be appropriately defined by the relationship between the probe and the vein (LA, SA, or OA) and by the relationship between the probe and the needle (OP or IP)¹² (Figure 3). The seven steps of the RaFeVA protocol take into account different visualization

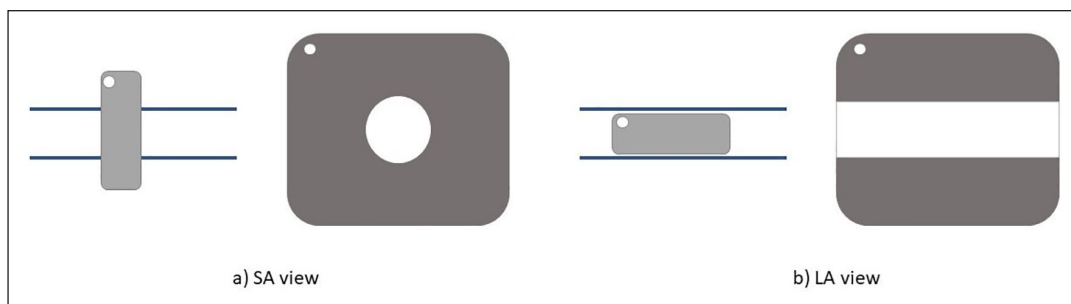


Figure 1. Visualization of the vein in short-axis (a) and in long-axis (b).

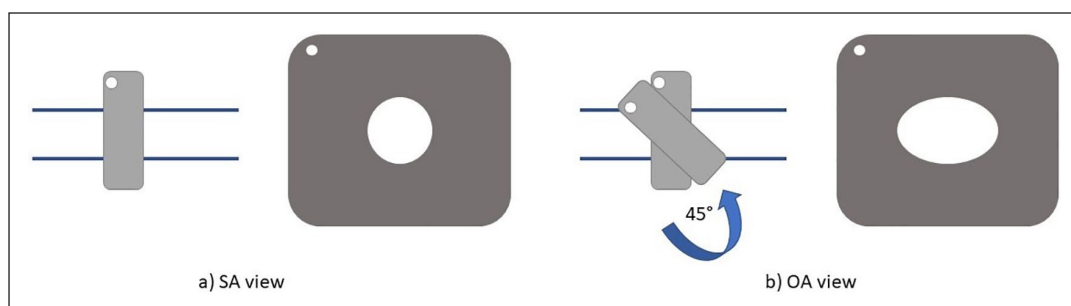


Figure 2. Transition from short-axis (a) view to oblique-axis view (b).

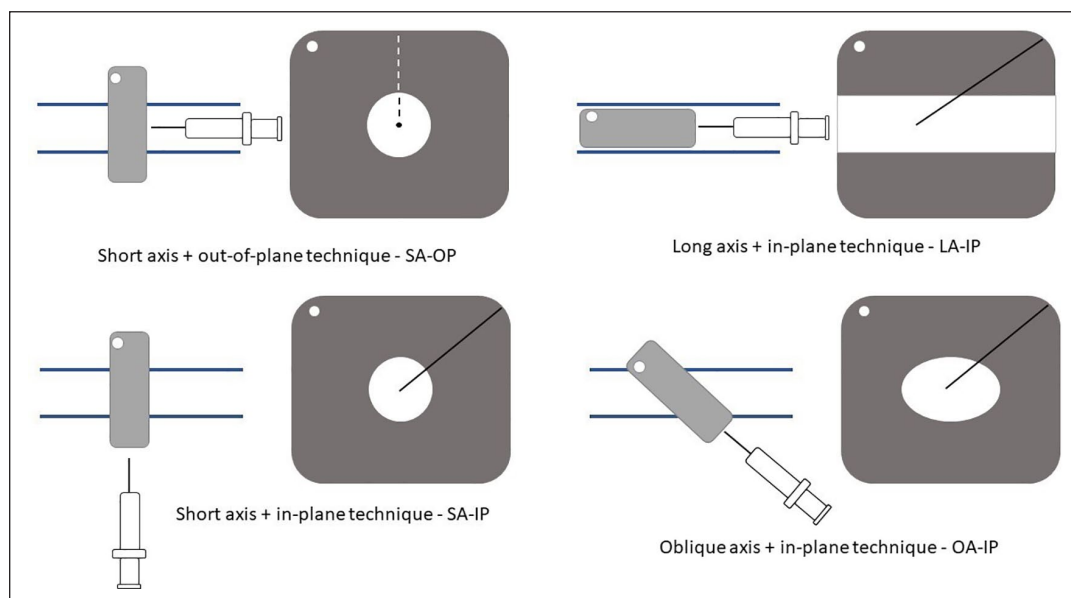


Figure 3. Techniques for US guided cannulation.

of the vessels (SA, LA, and OA), proposing different venipuncture techniques (OP and IP).

Step I

The RaFeVA starts at the inguinal groove, with the probe in a transverse position, perpendicular to the skin, where it is possible to identify the common femoral artery (CFA)

and the common femoral vein (CFV), both of them in short axis (Figure 4(a)).

The CFV is located medially to the CFA at a slightly deeper level; anatomical variables in this area are infrequent. In this first step, the CFV is assessed in terms of depth, size and patency (as assessed by probe compression). Therefore, in this step it is possible to proceed to a US guided venipuncture of the CFV with the SA, OOP approach (Figure 4(b)).

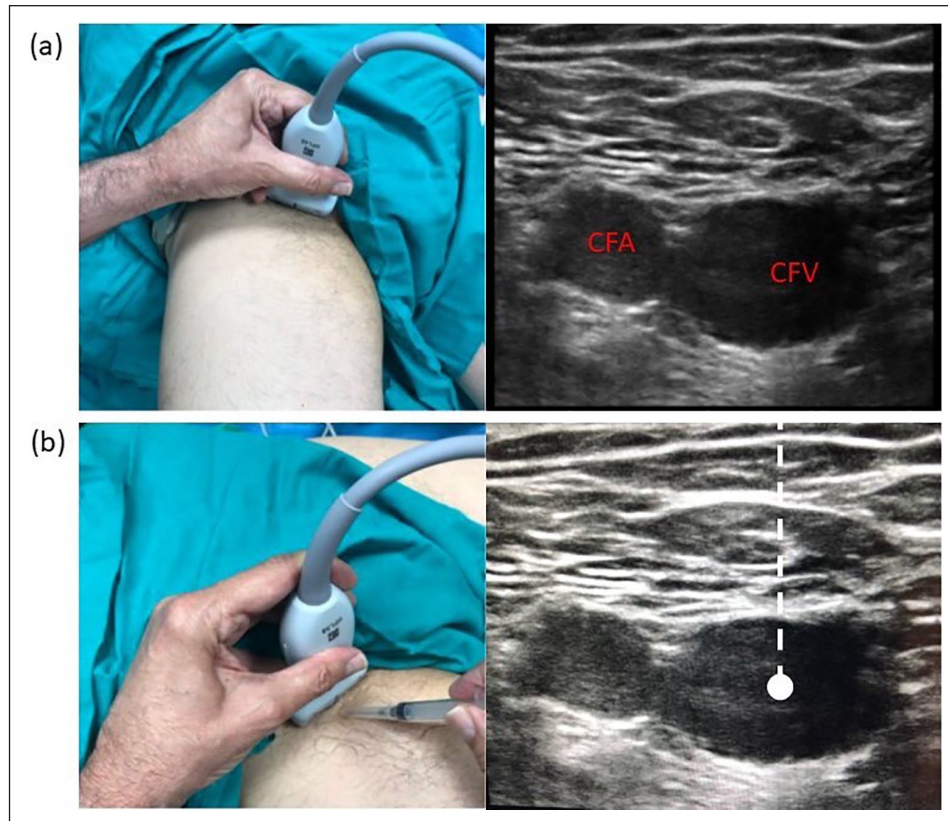


Figure 4. Step 1: (a) visualization of common femoral artery (CFA) and common femoral vein (CFV) in short axis, at the inguinal ligament level, and (b) US guided venipuncture of common femoral vein (CFV) in short axis out-of-plane (SA-OP) technique.

Step 2

Placing the CFV in SA view in the center of the probe and making a 90° rotation of the probe it is possible to switch to a visualization of the transition between CFV and external iliac vein (EIV) in LA (Figure 5(a)).

This visualization allows to assess the longitudinal axis of the veins and its course; losing the panoramic view of the transversal scan, it is not possible to evaluate the relationships of the vessel with the surrounding vascular and nervous structures. In this step it is possible to proceed with a US guided venipuncture of the CFV or of the EIV (i.e. before or after the ligament) with LA/IP approach (Figure 5(b)).

Step 3

After a new rotation of the probe by 90° to return to a SA view, moving the probe caudally, we come to the next step, that is, the visualization of CFA, CFV and saphenous vein (SV), in SA view (Figure 6).

Step 4

The evaluation of the vascular structures continues sliding the probe downward, far from the groin, still in a transverse view. In step 4, the probe visualizes the superficial

femoral artery (SFA), the deep femoral artery (DFA) and the CFV, all in SA (Figure 7).

Step 5

From step 4, moving the probe even more caudally, it is possible to visualize simultaneously the SFA, the DFA, the superficial femoral vein (SFV), and the deep femoral vein (DFV), all in SA (Figure 8). The SFV and the DFV are located in a slightly deeper plane than the corresponding arteries.

Step 6

From the position described in step 5, the probe slides caudally, toward mid-thigh. At this level it is possible to visualize the SFA and the SFV in SA. The artery is usually located immediately above the vein, so that a SA/OOP approach might be unpractical (Figure 9).

Step 7

From the position described in step 6, performing a 45° rotation of the probe, it is possible to obtain an OA view of the same vascular structures described in the previous step, SFA and SFV (Figure 10(a)). This the ideal position for

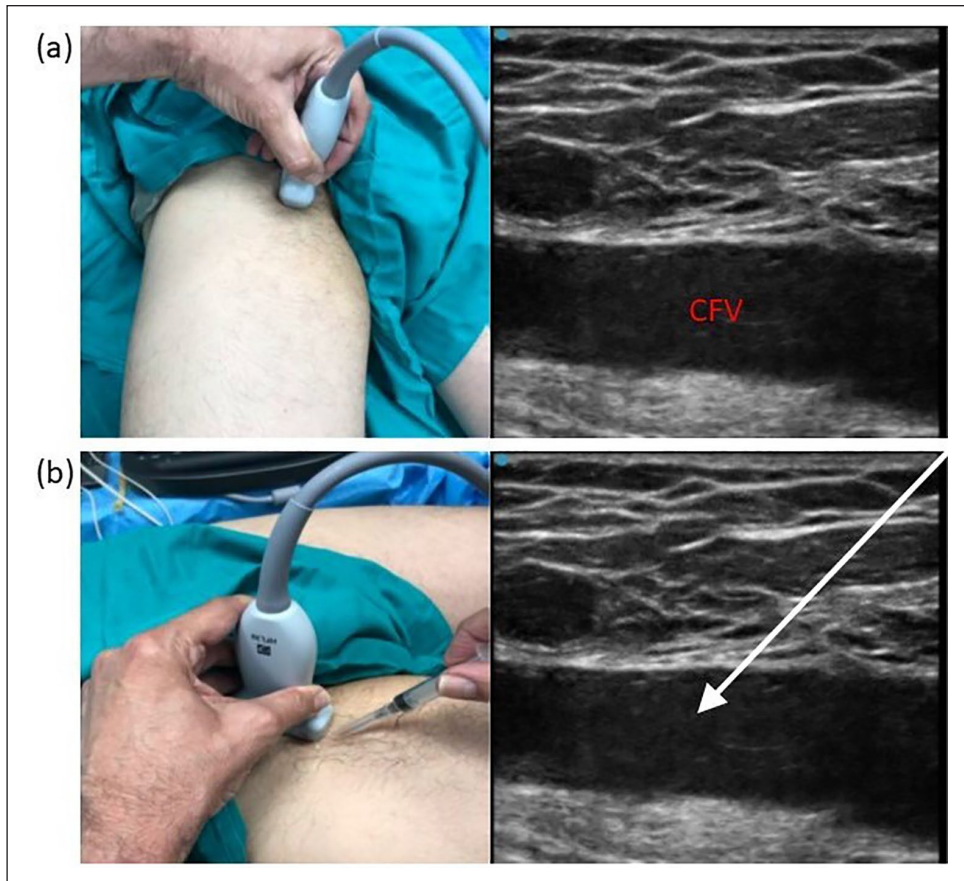


Figure 5. Step 2: (a) visualization of the common femoral vein (CFV) and external iliac vein in long axis, and (b) US guided venipuncture of common femoral vein (CFV) or external iliac vein in long axis in-plane (LA-IP) technique.

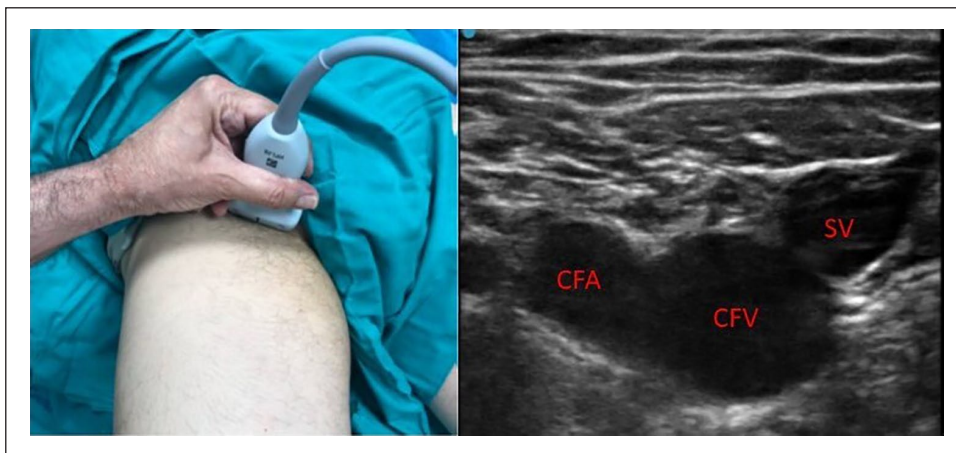


Figure 6. Step 3 visualization of the common femoral artery (CFA), common femoral vein (CFV) and saphenous vein (SV), in short axis.

performing an US guided venipuncture of the SFV with an OA/IP approach (Figure 10(b)).

Conclusion

The use of ultrasound in vascular access has clear evidence of efficacy for both venous and arterial cannulation. In all

phases of venous cannulation procedures, a correct use of ultrasound allows to improve the performance of the procedures, making them safer, faster, and more effective. The advantages of ultrasound are not exclusive to the procedural phase but accompany the performance of all procedures from preliminary assessment to early identification of puncture-related complications.

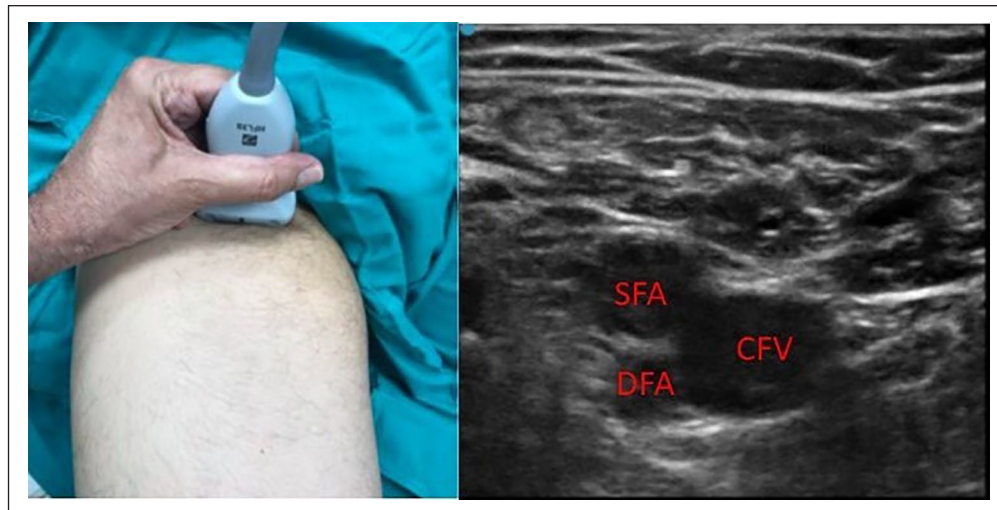


Figure 7. Step 4 visualization of the superficial femoral artery (SFA), the deep femoral artery (DFA) and the common femoral vein (CFV), in short axis.

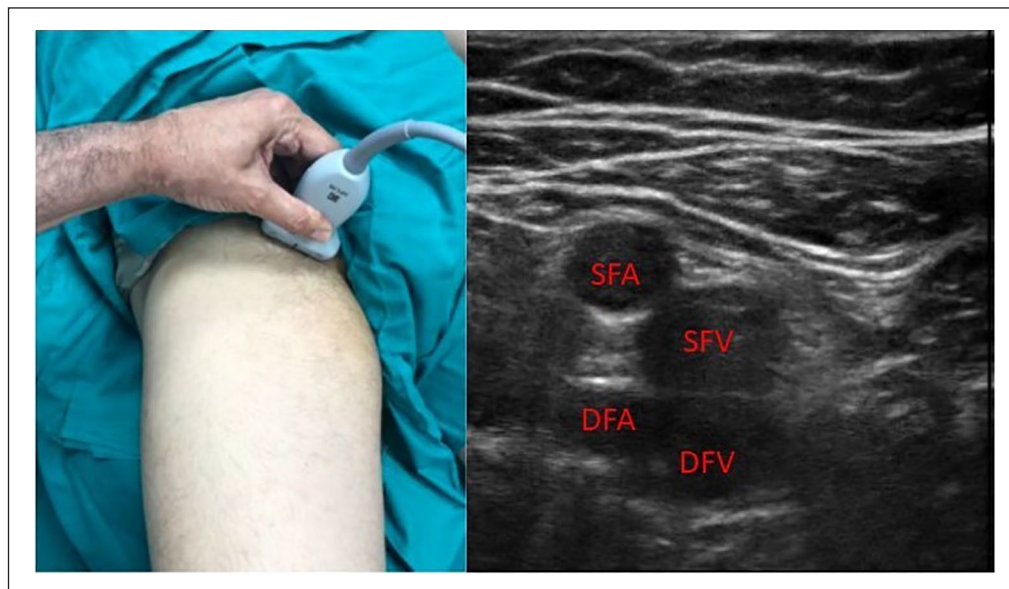


Figure 8. Step 5 visualization of the superficial femoral artery (SFA), the deep femoral artery (DFA), the superficial femoral vein (SFV), and the deep femoral vein (DFV), in short axis.

The preliminary ultrasound evaluation of the vessels allows to evaluate the venous patrimony, the depth and size of the veins, the presence of any physiological anomalies or pathological alterations, as well as the relationships with other nearby arterial or nervous structures. Therefore, a well performed preliminary ultrasound evaluation allows to choose the appropriate vein also in consideration of an adequate exit site location.

The RaFeVA protocol is a rapid and effective tool for a systematic ultrasound evaluation of the veins at different levels of the lower limb, from the groin to the middle of the thigh, with the aim of choosing the best approach and the

best location for positioning of different types of FICC: not tunneled FICCs with exit-site at the groin (venipuncture of the CFV); tunneled FICCs with exit-site at mid thigh or in the abdominal area (venipuncture of CFV + tunneling); not tunneled FICC with exit-site at mid thigh (venipuncture of SFV).

While the first option will be ideal for emergency central venous device and for short term dialysis catheters, the second and the third option will be appropriate for all other non-emergency clinical situations that may require a femoral access (often, because of superior vena cava obstruction), but only for a short-medium period of time. Long

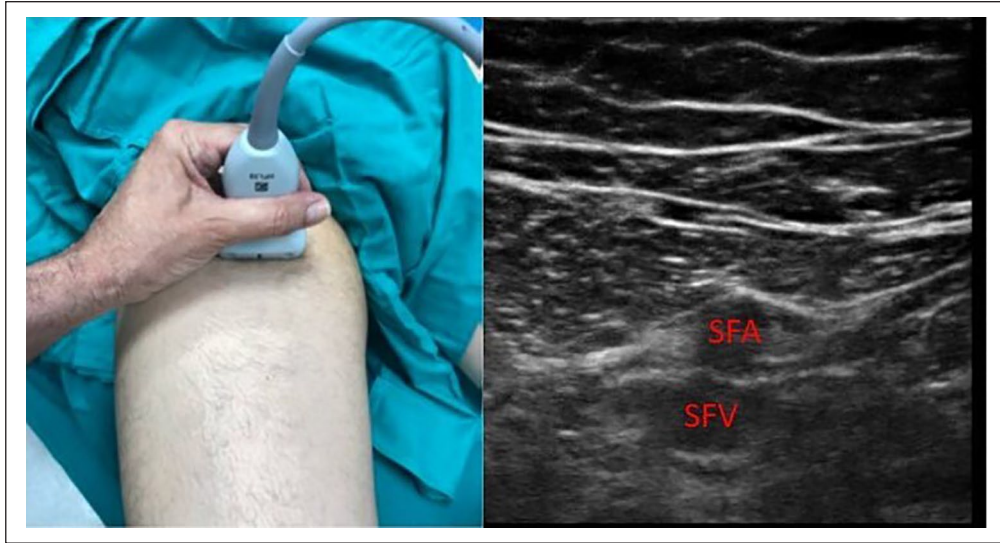


Figure 9. Step 6 visualization of the superficial femoral artery (SFA) and the superficial femoral vein (SFV), in short axis.

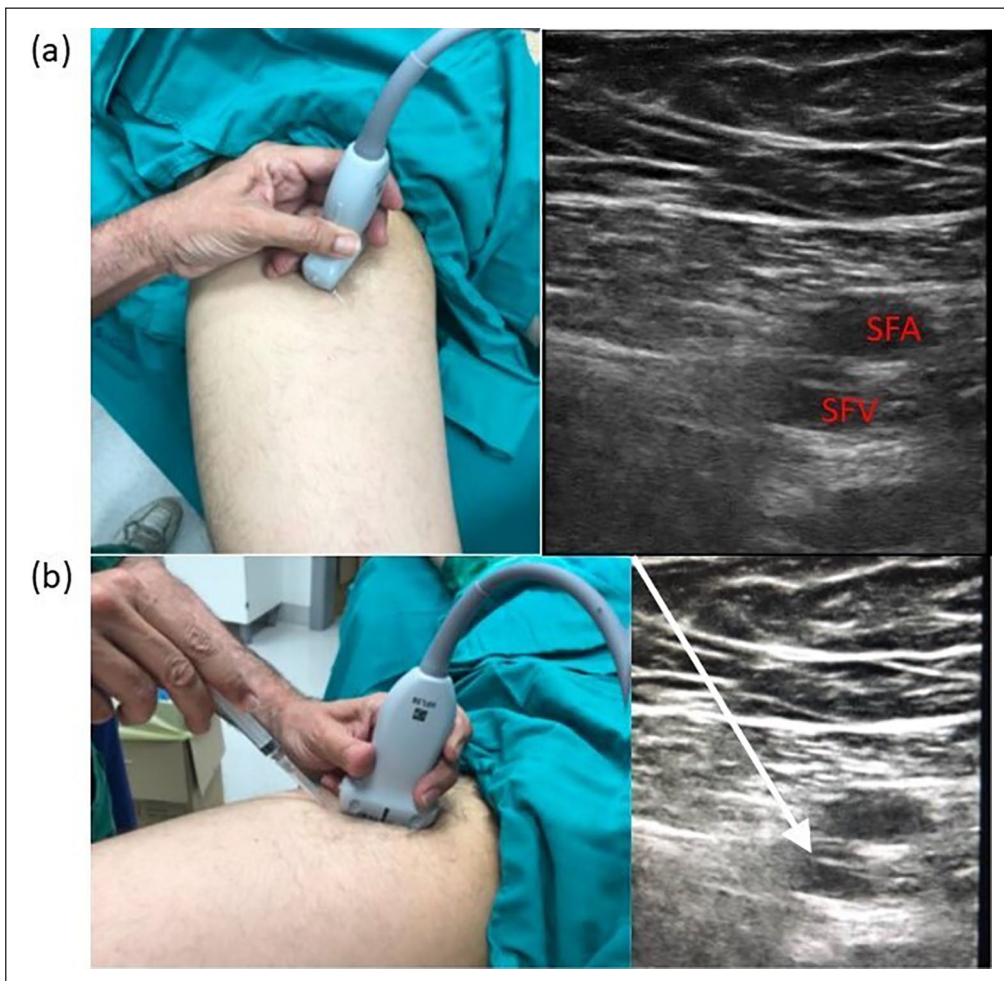


Figure 10. Step 7: (a) visualization of superficial femoral artery (SFA) and superficial femoral vein (SFV) in oblique-axis, and (b) US guided venipuncture of the superficial femoral vein in an oblique axis in-plane (OA-IP) technique.

term femoral access (months or years) will necessarily imply the second option, but either using a cuffed-tunneled catheter or using a non-cuffed tunneled catheter with subcutaneously anchored securement.

In all cases, RaFeVA will allow a detailed anatomical assessment before proceeding with the venous cannulation procedure, so to optimize the maneuver (reduction of cannulation time and of number of attempts, avoidance of surrounding structures that could be accidentally damaged during the venous catheterization, etc.).

Declaration of conflicting interests

The author(s) declared no potential conflicts of interest with respect to the research, authorship, and/or publication of this article.

Funding

The author(s) received no financial support for the research, authorship, and/or publication of this article.

ORCID iDs

Fabrizio Brescia  <https://orcid.org/0000-0002-6892-474X>

Mauro Pittiruti  <https://orcid.org/0000-0002-2225-7654>

Matthew Ostroff  <https://orcid.org/0000-0001-5417-5621>

References

- Lamperti M, Biasucci DG, Disma N, et al. European Society of Anaesthesiology guidelines on peri-operative use of ultrasound-guided for vascular access (PERSEUS vascular access). *Eur J Anaesthesiol* 2020; 37(5): 344–376.
- Lamperti M, Bodenham AR, Pittiruti M, et al. International evidence-based recommendations on ultrasound-guided vascular access. *Intensive Care Med* 2012; 38(7): 1105–1117.
- Pittiruti M, Hamilton H, Biffi R, et al. ESPEN guidelines on parenteral nutrition: central venous catheters (access, care, diagnosis and therapy of complications). *Clin Nutr* 2009; 28(4): 365–377.
- Gorski L, Hadaway L, Hagle M, et al. Infusion therapy standards of practice. *J Infus Nurs* 2016; 39(1S): S1–S159.
- Moureau N, Lamperti M, Kelly LJ, et al. Evidence-based consensus on the insertion of central venous access devices: definition of minimal requirements for training. *Br J Anaesth* 2013; 110(3): 347–356.
- Bodenham A, Babu S, Bennett J, et al. Association of Anaesthetists of Great Britain and Ireland: safe vascular access 2016. *Anaesthesia* 2016; 71(5): 573–585.
- Bouaziz H, Zetlaoui PJ, Pierre S, et al. Guidelines on the use of ultrasound guidance for vascular access. *Anaesth Crit Care Pain Med* 2015; 34(1): 65–69.
- Wu SY, Ling Q, Cao LH, et al. Real-time two-dimensional ultrasound guidance for central venous cannulation: a meta-analysis. *Anesthesiology* 2013; 118(2): 361–375.
- Troianos CA, Hartman GS, Glas KE, et al. Special articles: guidelines for performing ultrasound guided vascular cannulation: recommendations of the American Society of Echocardiography and the Society of Cardiovascular Anesthesiologists. *Anesth Analg* 2012; 114(1): 46–72.
- Biasucci DG. Ultrasound based innovations for interventional procedures: the paradigmatic case of central venous access. *Minerva Anesthesiol* 2020; 86(2): 121–123.
- Spencer TR and Pittiruti M. Rapid Central Vein Assessment (RaCeVA): a systematic, standardized approach for ultrasound assessment before central venous catheterization. *J Vasc Access* 2019; 20(3): 239–249.
- Biasucci DG, La Greca A, Scoppettuolo G, et al. Ultrasound-guided central venous catheterization: it is high time to use a correct terminology. *Crit Care Med* 2015; 43(9): e394–e396.
- Brescia F, Biasucci DG, Fabiani F, et al. A novel ultrasound-guided approach to the axillary vein: oblique-axis view combined with in-plane puncture. *J Vasc Access* 2019; 20(6): 763–768.
- Biasucci DG, La Greca A, Scoppettuolo G, et al. What's really new in the field of vascular access? Towards a global use of ultrasound. *Intensive Care Med* 2015; 41(4): 731–733.
- Vezzani A, Brusasco C, Palermo S, et al. Ultrasound localization of central vein catheter and detection of postprocedural pneumothorax: an alternative to chest radiography. *Crit Care Med* 2010; 38(2): 533–538.
- Galloway S and Bodenham A. Ultrasound imaging of the axillary vein—anatomical basis for central venous access. *Br J Anaesth* 2003; 90(5): 589–595.
- Pittiruti M and LaGreca A. How to choose the most appropriate ultrasound-guided approach for central line insertion: introducing the rapid central venous assessment protocol. In: P Lumb and D Karakitsos (eds.) *Critical care ultrasound*. Philadelphia, PA: Saunders, 2014, pp. 76–79.
- Saul T, Doctor M, Kaban NL, et al. The ultrasound-only central venous catheter placement and confirmation procedure. *J Ultrasound Med* 2015; 34(7): 1301–1306.
- Pittiruti M, LaGreca A, Scoppettuolo G, et al. Ultrasound-guided vs ultrasound-assisted central venous catheterization. *Crit Care* 2007; 11(2): P158.
- Blanco P. Ultrasound-guided vascular cannulation in critical care patients: a practical review. *Med Intensiva* 2016; 40(9): 560–571.
- Sharma A, Bodenham AR and Mallick A. Ultrasound guided infraclavicular axillary vein cannulation for central venous access. *Br J Anaesth* 2004; 93(2): 188–192.
- Blanco P and Volpicelli G. Common pitfalls in point-of-care ultrasound: a practical guide for emergency and critical care physicians. *Crit Ultrasound J* 2016; 8(1): 15.
- La Greca A, Biasucci DG, Emoli A, et al. Improving the “global use” of ultrasound for central venous access: a new supraclavicular scan by microconvex probe. *Crit Ultrasound J* 2014; 6(S2): A11.
- Maury E, Guglielminotti J, Alzieu M, et al. Ultrasonic examination: an alternative to chest radiography after central venous catheter insertion? *Am J Respir Crit Care Med* 2001; 164(3): 403–405.
- Bedel J, Vallée F, Mari A, et al. Guidewire localization by transthoracic echocardiography during central venous catheter insertion: a periprocedural method to evaluate catheter placement. *Intensive Care Med* 2013; 39(11): 1932–1937.
- National Institute for Clinical Excellence. *NICE technology appraisal guidance No 49: guidance on the use of*

- ultrasound locating devices for placing central venous catheters*. London: NICE; September 2002.
27. Apfelbaum JL, Rupp SM, Tung A, et al. Practice guidelines for central venous access 2020 an updated report by the american society of anesthesiologist task force on central venous access. *Anesthesiology* 2020; 132(1): 8–43.
 28. Iacobone E, Elisei D, Gattari D, et al. Transthoracic echocardiography as bedside technique to verify tip location of central venous catheters in patients with atrial arrhythmia. *J Vasc Access*. Epub ahead of print March 2020. DOI: 10.1177/1129729820905200.
 29. Saugel B, Scheeren TW and Teboul JL. Ultrasound-guided central venous catheter placement: a structured review and recommendations for clinical practice. *Crit Care* 2017; 21(1): 225.
 30. Emoli A, Cappuccio S, Marche B, et al. The ISP (Safe Insertion of PICCs) protocol: a bundle of 8 recommendations to minimize the complications related to the peripherally inserted central venous catheters (PICC). *Assist Infirm Ric* 2014; 33(2): 82–89.
 31. Hughes P, Scott C and Bodenham A. Ultrasonography of the femoral vessels in the groin: implications for vascular access. *Anaesthesia* 2000; 55(12): 1198–1202.
 32. O’Grady NP, Alexander M, Burns LA, et al. Guidelines for the prevention of intravascular catheter-related infections. *Clin Infect Dis* 2011; 52(9): e162–e193.
 33. Bishop L, Dougherty L, Bodenham A, et al. Guidelines on the insertion and management of central venous access devices in adults. *Int J Lab Hematol* 2007; 29(4): 261–278.
 34. Brass P, Hellmich M, Kolodziej L, et al. Ultrasound guidance versus anatomical landmarks for subclavian or femoral vein catheterization. *Cochrane Database Syst Rev* 2015; 1(1): CD011447.